

## **PART B: MRI AND COMPUTED IMAGING**

**SOLVE AS MUCH AS YOU CAN.**

**I. Answer the following questions by selecting ONE choice:**

B1. [1.5 points] MIP is a method for:

- One) Reconstructing MRA volumes
- Two) Visualizing images of vessels from acquired MRA volume
- Three) Acquiring MRA volumes
- Four) Reducing artifacts in MRA
- Five) Reducing saturation artifacts in MRA

B2. [1.5 points] In MRA, to overcome the saturation artifacts in 3D and the low SNR in 2D TOF acquisition, the following technique can be used:

- One) Black blood MRA
- Two) Bright Blood MRA
- Three) MIP
- Four) MOTSA
- Five) TONE

B3. [1.5 points] STIR imaging sequence is used to:

- One) Label the fat component for subsequent segmentation
- Two) Make the fat component contrast higher for better visualization
- Three) Make the fat components in the image disappear
- Four) Improve the signal-to-noise ratio in fat areas
- Five) Provide images of only fat tissues

B4. [1.5 points] To acquire a T1-weighted image, we must use:

- One) Spin echo sequence with long TR and Long TE
- Two) Spin echo sequence with short TR and short TE
- Three) Spin echo sequence with long TR and short TE
- Four) Gradient echo sequence with long TR and long TE
- Five) Gradient echo sequence with short TR and short TE

B5. [1.5 points] Increasing the resolution of a sequence for the same FOV in a phase encoding direction results in:

- One) The same SNR
- Two) A higher SNR
- Three) A lower SNR
- Four) Unpredictable change in SNR
- Five) Other: .....

B6. [1.5 points] In order to increase the resolution for a given FOV in the frequency encoding direction, the best SNR is obtained when this increase is obtained using:

- One) A higher BW at the same read-out gradient and same sampling duration
- Two) The same BW at a lower read-out gradient and higher sampling duration
- Three) A higher BW at a lower read-out gradient and same sampling duration
- Four) The same BW at the same read-out gradient and higher sampling duration
- Five) A higher BW at a lower read-out gradient and higher sampling duration

B7. [1.5 points] For the same matrix ( $N \times N \times N$ ) and FOV, the ratio of the SNR for 3D acquisition to that for multi-slice acquisition is,

- One)  $N$
- Two)  $1/N$
- Three)  $\sqrt{N}$
- Four)  $1/\sqrt{N}$
- Five)  $1$

B8. [1.5 points] Aliasing artifact in the phase encoding direction results from:

- One) A number of phase encoding steps that is too small
- Two) A number of phase encoding steps that is too large
- Three) A phase encoding step that is too small
- Four) A phase encoding step that is too large
- Five) Under-sampling the received time-domain echoes

B9. [1.5 points] Truncation artifact results in images characterized by:

- One) Apparent ringing
- Two) Ghosts
- Three) Geometric distortion
- Four) Venetian blind distortion
- Five) Saturation effects

B10. [1.5 points] The special requirements of mammography are:

- One) High energy x-ray, high spatial resolution, and long exposure time
- Two) Low energy x-ray, high spatial resolution and short exposure time
- Three) High energy x-ray and high spatial resolution at any exposure time
- Four) Low energy x-ray at any resolution and exposure time
- Five) Medium energy x-ray and low spatial resolution at short exposure time

B11. [1.5 points] If a material with 1.5 times the attenuation coefficient of water has a CT number of 500, the CT number of another material that is 0.75 that of water is,

- One)  $-500$
- Two)  $-250$
- Three)  $250$
- Four)  $1000$
- Five)  $-1000$

B12. [1.5 points] Dynamic spatial reconstruction system is characterized by:

- a) Fast acquisition and reconstruction of 3D volumes using computed tomography
- b) Real-time visualization of acquired 3D volumes
- c) Dynamic imaging in MRI
- d) Spatial-temporal analysis in functional imaging
- e) A fast processing for MRI reconstruction

B13. [1.5 points] PET technique relies on:

- One) Tomographic reconstruction of attenuation coefficients maps
- Two) Tomographic reconstruction of photon emission sources
- Three) Tomographic reconstruction of annihilation radiation using coincidence detection
- Four) Tomographic reconstruction of attenuated alpha particles
- Five) Tomographic reconstruction of attenuated beta particles

B14. [1.5 points] SPECT reconstruction is more difficult than conventional CT reconstruction because:

- One) The detectors used to collect the data are less efficient
- Two) The injected radioactive materials are difficult to handle
- Three) It is required to compute both attenuation and photon source intensity maps
- Four) It is required to compute higher resolution images
- Five) The computers used in SPECT are less sophisticated

B15. [1.5 points] Longitudinal relaxation is longer in which type of tissues?

- One) water > solids > fat
- Two) fat > solids > water
- Three) solids > water > fat
- Four) water > fat > solids
- Five) solids = water = fat

B16. [1.5 points] A gradient echo sequence with a short TR and long TE has,

- One) T1-weighted contrast only
- Two) T2-weighted contrast only
- Three) T2\*-weighted contrast only
- Four) Mixed T1- and T2-weighted contrast
- Five) Mixed T1- and T2\*-weighted contrast

B17. [1.5 points] It is required to collect a T1-weighted image of a small 4cm x 4cm area within the brain tissue at maximum signal-to-noise ratio. The outline of the brain fits into a 20cm x 20cm FOV and is fairly symmetric within this area. The center of the region of interest is away from the magnet isocenter by 2 cm in the x-direction and 1 cm in the y-direction. The optimal FOV to be used in this case should be:

- One) 20cm x 20cm
- Two) 4cm x 4cm
- Three) 14cm x 13cm
- Four) 16cm x 15cm
- Five) Other: .....

B18. [1.5 points] In designing an RF pulse to select a 5mm slice in a 1.5T magnet, if the slice selection gradient is set at 5mT/m and the desired flip angle is  $\pi/6$ , a proper design for the duration of a rectangular RF pulse can be selected approximately as:

- One) 1 msec
- Two) 2 msec
- Three) 8 nsec
- Four) 1 nsec
- Five) Other: .....

B19. [1.5 points] To acquire an oblique slice that makes an angle of 45 degrees with x-, y- and z-axes, the slice selection design consists of:

- One) Three similar RF pulses in x-, y-, and z-directions with no gradients
- Two) One RF pulse and no gradients
- Three) Two RF pulses in x- and y-directions and a gradient in z-direction
- Four) One RF pulse and equal gradients in x-, y-, and z-directions
- Five) Other: .....

B20. [1.5 points] In a multi-slice TOF MRA imaging sequence, the scan parameters were: TR/TE: 300/20 msec, FOV: 20cm x 20cm, Matrix 256x192, Number of slices: 128, slice thickness: 5mm, NEX: 2, flip angle: 30 degrees. The shortest total acquisition time for this sequence is approximately:

- One) 18 minutes
- Two) 245 minutes
- Three) 2 minutes
- Four) 9 minutes
- Five) Other: .....

B21. [1.5 points] In TOF MRA, the inherent contrast mechanism used to distinguish the vessels is:

- One) Gadolinium
- Two) Fluid nature of the blood
- Three) T2 characteristics of the blood
- Four) Blood motion
- Five) RBCs

B22. [1.5 points] The main disadvantage of half NEX acquisition is:

- One) Its low SNR
- Two) Its fast acquisition time
- Three) Its inherent T1-weighting
- Four) Its low contrast
- Five) Its severe motion artifacts

B23. [1.5 points] A fundamental limitation of MRI is:

- One) Its inability to image soft tissues accurately
- Two) Its inherent low SNR
- Three) Its inability to image tissues near air or bone interfaces
- Four) Its low signal because of attenuation effects
- Five) Its volumetric acquisition

B24. [1.5 points] The k-space trajectory can be fully determined by:

- One) Knowing the RF pulse and the slice selection gradients
- Two) Knowing the full gradient history within the selected slice
- Three) Knowing the data acquisition period relative to applied gradients
- Four) Both a) and b)
- Five) Both b) and c)

## **II. Answer the following questions by either TRUE or FALSE:**

B25. [1 point] The B0 magnetic field is turned on and off to start and end a scan

B26. [1 point] The shim coils are used to improve the homogeneity of B0 field

B27. [1 point] The B1 field is generated using two coils in the x- and y-directions

B28. [1 point] The k-space trajectory depends on the flip angle of the RF pulse

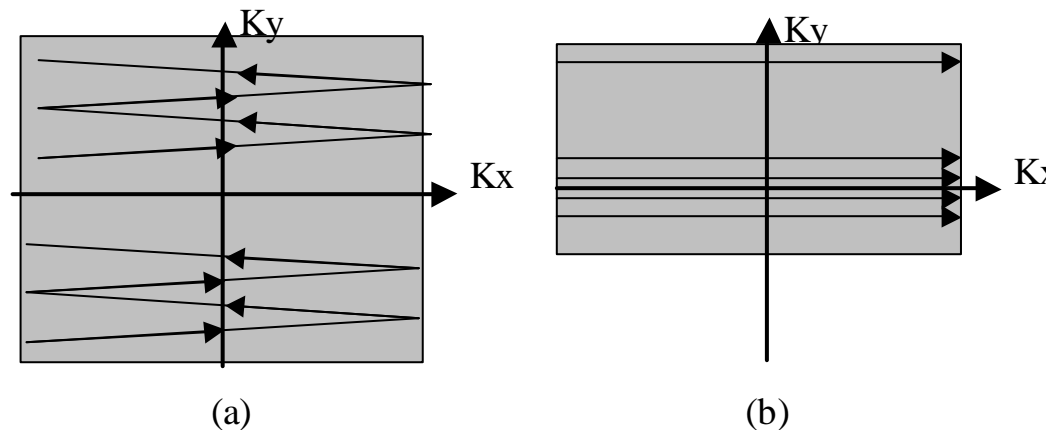
B29. [1 point] Half NEX sequences are used to improve SNR

B30. [1 point] Cross-talk results from overlapped slice profiles

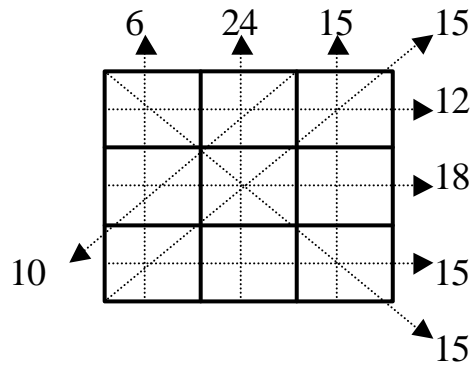
B31. 1 point] Partial volume artifacts results from small slice thickness

- B32. [1 point]  $T2^*$  is completely independent from  $T2$  relaxation  
 B33. [1 point] Spin echo is used only when  $T2$ -weighting is desired  
 B34. [1 point] CT can be used effectively near air or bone tissue interfaces

B35. [4 points] Draw a properly labeled  $T2^*$ -weighted sequence (a) and  $T1$ -weighted sequence (b) that have the shown k-space trajectories:



B36. [3 points] Solve the following reconstruction problem using ART:



**BEST OF LUCK**